

Reconstruction with hamstring autograft of atraumatic simultaneous ruptures of the bilateral quadriceps tendons: A novel technique

Reconstruction with hamstring autograft of ruptures of the bilateral quadriceps tendons

Burak Kusu¹, Fatih Dogar², Duran Topak², Yakup Ekinci³, Kaan Gürbüz³

¹Department of Orthopaedics and Traumatology, Kahramanmaraş Pazarcık State Hospital, Kahramanmaraş

²Department of Orthopedics and Traumatology, Faculty of Medicine, Kahramanmaraş Sutcu Imam University, Kahramanmaraş

³Department of Orthopaedics and Traumatology, Kayseri City Education and Research Hospital, Kayseri, Turkey

Abstract

Bilateral spontaneous quadriceps tendon rupture is a very uncommon phenomenon recorded in a few cases, but unilateral traumatic quadriceps tendon rupture is a rather common orthopedic pathology. In addition, it is related to systemic (e.g., diabetes mellitus, hyperparathyroidism, gout, pseudogout, obesity, steroid usage) and autoimmune diseases as well as most chronic renal failure (CRF). The occurrence of bilateral atraumatic simultaneous quadriceps tendon ruptures in CRF is most likely associated with the duration of renal disease and the duration of dialysis. Here we present an atraumatic spontaneous rupture of both quadriceps tendons with tendon hamstring autograft in a previously diagnosed male patient with CRF repaired using a novel reconstruction technique. This technique, which we use in quadriceps tendon repair, is an easy and effective method that shows excellent results in early rehabilitation and knee joint movements and prevent early re-rupture.

Keywords

Quadriceps Tendon, Rupture, Reconstruction, Chronic Renal Failure, Novel Technique

DOI: 10.4328/ACAM.21569 Received: 2023-01-01 Accepted: 2023-04-29 Published Online: 2023-05-04 Printed: 2023-09-25 Ann Clin Anal Med 2023;14(Suppl 2):S203-206

Corresponding Author: Burak Kusu, Department of Orthopaedics and Traumatology, Kahramanmaraş Pazarcık State Hospital, 46700, Pazarcık, Kahramanmaraş, Turkey.

E-mail: dr.burakkusu@hotmail.com P: +90 507 192 73 13

Corresponding Author ORCID ID: <https://orcid.org/0000-0002-1082-2206>

Introduction

Bilateral spontaneous simultaneous rupture of the quadriceps tendon is very rare and almost always related to comorbidities although unilateral quadriceps tendon rupture is a relatively common injury [1]. Spontaneous tendon ruptures, characterized by uremic tendinopathy, were seen in about 15% of patients with CRF. Bilateral concurrent atraumatic quadriceps tendon ruptures in chronic kidney disease are almost certainly related to the duration of the renal disease and the duration of dialysis [2].

Here we present a case of a previously diagnosed CRF male patient, repaired with the new reconstruction technique, an atraumatic spontaneous rupture of bilateral quadriceps tendons with tendon autografting.

Case Report

A 40-year-old male patient who had been on dialysis for 10 years due to CRF was standing after a routine dialysis session without any known trauma. As a result, a crunch from both knees was heard, as was an immediate beginning of pain. The patient was then unable to stand or ambulate after that. On physical examination at the emergency department, a severe effusion was noted in the suprapatellar space in both knees. Moreover, no active extension against gravity was feasible,

and patellar reflex could not be induced on either side. A 1–1.5 cm gap was found at the attachment site of the quadriceps tendons to the superior patella on palpation in the suprapatellar region of the bilateral knees (Figure 1a). X-ray findings showed a patella Baja image in both knees. Both knees had radiographic indications of osteoarthritis, including restricted joint space, osteophyte forms, and subchondral sclerosis (Figure 1b). In both knee joints, T2-weighted magnetic resonance imaging (MRI) revealed a discontinuity between the distal quadriceps tendon and the upper pole of the patella, with the intervening region filled with hyperintense signal intensity in stark contrast to the tendon's hypointense signal intensity. Additionally, on both sides, a minor joint effusion was observed in the suprapatellar region (Figure 1c).

Surgical Technique

The patient was applied spinal anesthesia and was placed in the supine position. Consequently, preoperative surgical preparations were performed. Approximately 3- to 4-cm longitudinal incision was made first through the proximal and distal of the right knee patella superior pole (Figure 2a). A massive hematoma in the suprapatellar space was cleared after the dissection (Figure 2b). A large gap with full-thickness quadriceps tendon rupture at the enthesis region on the proximal pole of the patella was observed (Figure 2c). A 2- to

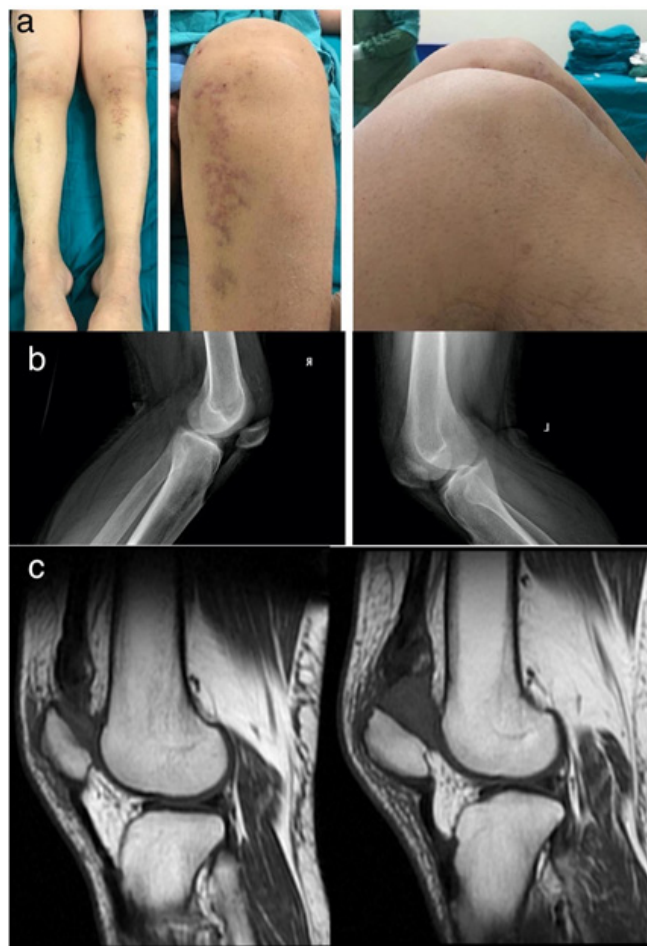


Figure 1. a: Preoperative clinical view of the knees at flexion, in which the gap formation can easily be seen as a groove at the superior border of the patella; b: X-rays of both knees preoperatively; c: Sagittal MRI views of both knees preoperatively.

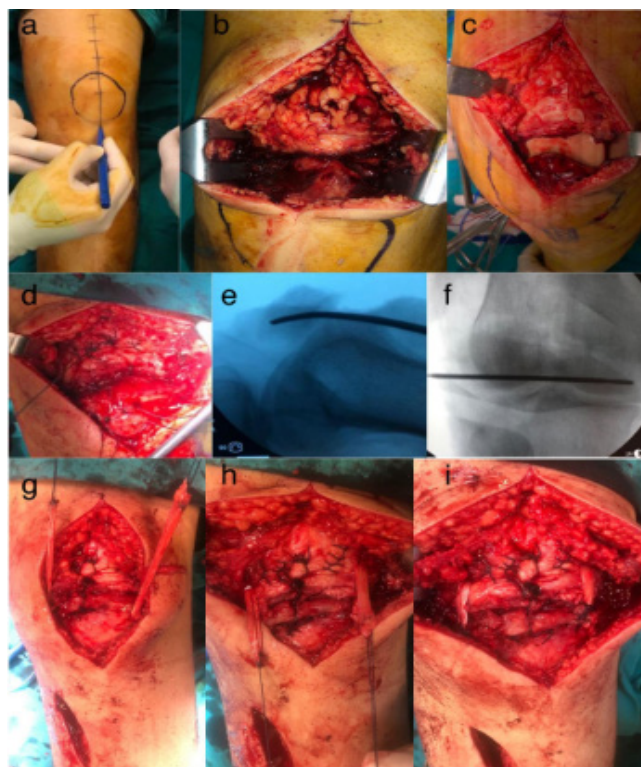


Figure 2. a: View of the surgical incision; b: Intraoperative view of the hematoma formed in the preoperatively seen gap; c: Intraoperative view of the muscles quadriceps tendon rupture; d: Intraoperative view of suturing the distal, central, medial and lateral parts of the quadriceps tendon through a 1.2 mm hole in the superior part of the patella after augmented with the Korocow suture technique; e, f: Fluoroscopic images of the transverse tunnel superior to the patella and passage of the Hamstring Tendon graft through the tunnel; g-i: Intraoperative view of suturing both ends of the hamstring tendon over the distal medial and lateral quadriceps tendon.

repair could not be performed for the quadriceps tendon. This obtained tendon was passed through the transverse tunnel in the patella and passed several times to bridge this defect in the quadriceps tendon. In another study carried out by Unlu et al. [8], two autograft tendons were used, and the quadriceps tendon was sutured end-to-end, then passed through the patella in the same way and sutured to the patellar tendon differently after passing through the quadriceps tendon. In our case report, different from the above study, after the quadriceps tendon was sutured to the patella with the end-to-end Krackow suture technique, a single autograft tendon was used, passed transversely through the patella, and passed through the quadriceps tendon medially and laterally, and then sutured onto itself.

The Lysholm score was determined by Unlu et al. as a mean value of 89 points (good results) [8]. In addition, the range of motion (ROM) at flexion and lack of extension of the knees were 120° and 10° in the study by Unlu et al. [8]. In our case, the Lysholm score was 91 points (excellent result), and ROM at flexion and lack of extension of the knees were 130° and < -5°, respectively.

The current surgical method, which was applied to the patient of this study with a diagnosis of CRF and bilateral quadriceps tendon rupture, did not have a re-rupture after 2 years of follow-up, and nearly a full range of motion was reached. However, there are no studies in the literature with long-term results, although several repair methods have shown excellent results for bilateral quadriceps tendon ruptures.

As a result, bilateral spontaneous quadriceps tendon rupture is an extremely rare condition and can be seen in patients with systemic disease. Reinforcement with the Krackow suture method with the help of hamstring autograft has shown that this technique is an easy and effective method, which shows excellent results in early rehabilitation and knee joint movements and helps avoid early re-rupture.

Scientific Responsibility Statement

The authors declare that they are responsible for the article's scientific content including study design, data collection, analysis and interpretation, writing, some of the main line, or all of the preparation and scientific review of the contents and approval of the final version of the article.

Animal and human rights statement

All procedures performed in this study were in accordance with the ethical standards of the institutional and/or national research committee and with the 1964 Helsinki Declaration and its later amendments or comparable ethical standards. No animal or human studies were carried out by the authors for this article.

Conflict of interest

None of the authors received any type of financial support that could be considered potential conflict of interest regarding the manuscript or its submission.

References

1. Ellanti P, Davarinos N, Morris S, Rice J. Bilateral synchronous rupture of the quadriceps tendon. *Ir J Med Sci.* 2012;181(3):423-5.
2. Lim CH, Landon KJ, Chan GM. Bilateral Quadriceps Femoris Tendon Rupture in a Patient with Chronic Renal Insufficiency: A Case Report. *J Emerg Med.* 2016;51(4):e85-e87.
3. Garner MR, Gausden E, Berkes MB, Nguyen JT, Lorch DG. Extensor Mechanism Injuries of the Knee: Demographic Characteristics and Comorbidities from a Review of 726 Patient Records. *J Bone Joint Surg Am.* 2015;97(19):1592-96.
4. Krackow KA. The Krackow suture: how, when, and why. *Orthopedics.* 2008;31(9):931-3.
5. Pocock CA, Trikha SP, Bell JS. Delayed reconstruction of a quadriceps tendon. *Clin Orthop Relat Res.* 2008;466(1):221-4.
6. Okay E, Turgut MC, Tokyay A. Quadriceps reconstruction with suture anchor

and Achilles allograft combination in quadriceps tendon re-rupture after primary surgical repair: A novel technique. *Jt Dis Relat Surg.* 2021;32(3):798-803.

7. Leopardi P, Vico Gd, Rosa D, Cigala F, Maffulli N. Reconstruction of a chronic quadriceps tendon tear in a body builder. *Knee Surg Sports Traumatol Arthrosc.* 2006;14(10):1007-11.

8. Unlu MC, Kaynak G, Caliskan G, Birsel O, Kesmezacar H. Late repair of quadriceps tendon ruptures with free hamstring autograft augmentation and tension relief in patients with predisposing systemic diseases. *J Trauma.* 2011;71(4):1048-53.

How to cite this article:

Burak Kuscu, Fatih Dogar, Duran Topak, Yakup Ekinci, Kaan Gürbüz. Reconstruction with hamstring autograft of atraumatic simultaneous ruptures of the bilateral quadriceps tendons: A novel technique. *Ann Clin Anal Med* 2023;14(Suppl 2):S203-206